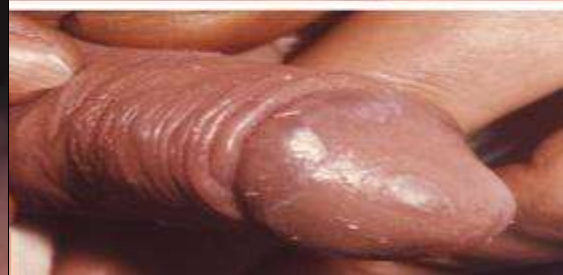
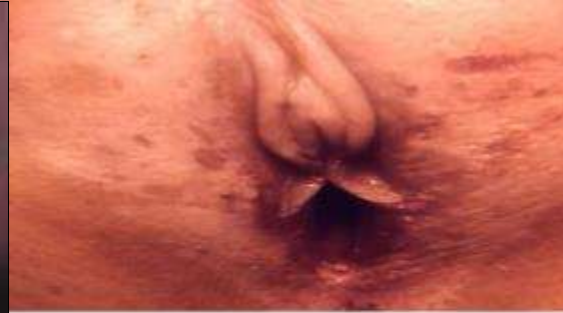
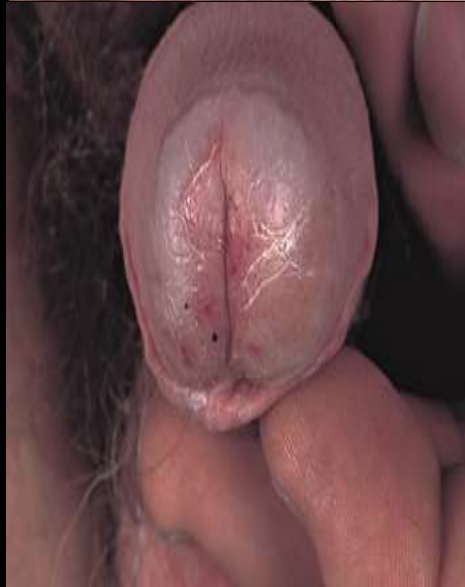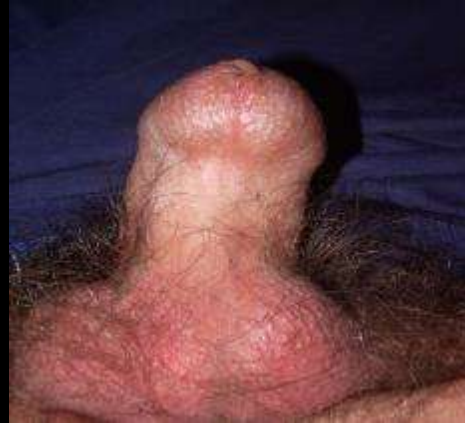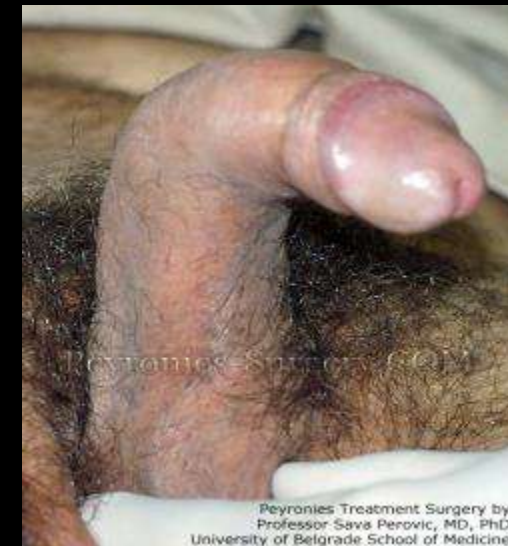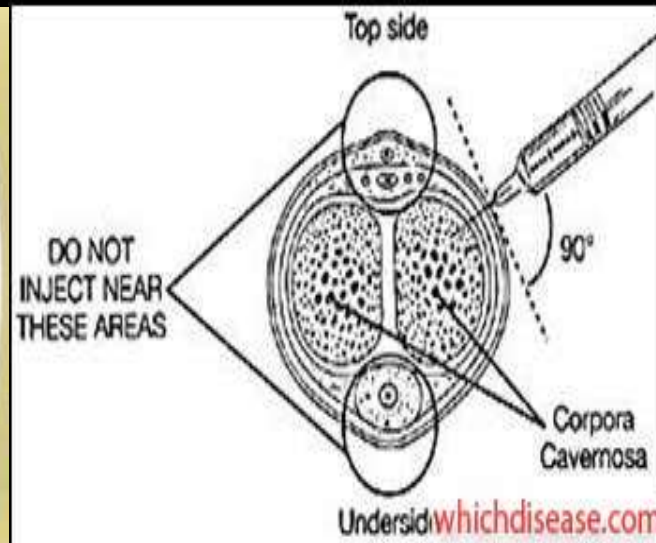
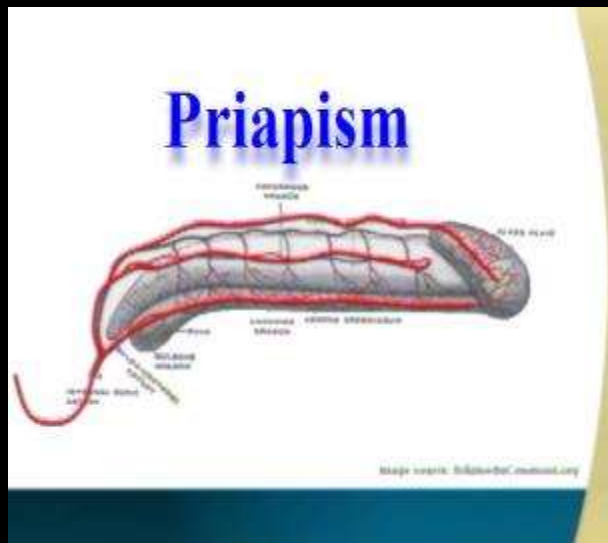
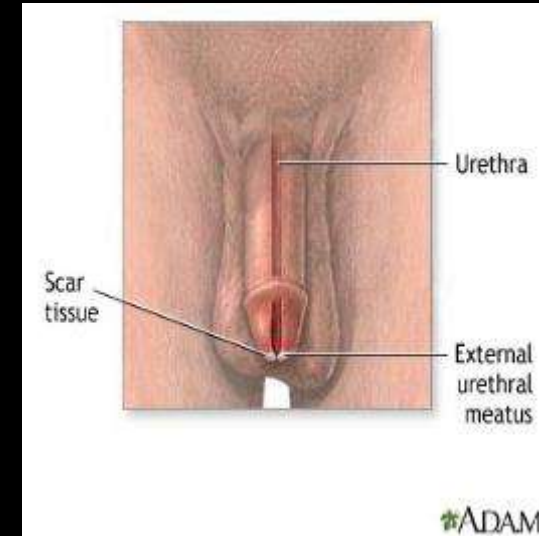
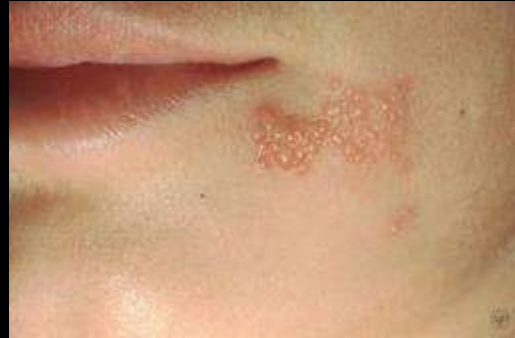# Genital Pathology

- Phimosis / Paraphimosis
- Balanitis
- Squamous cell lesion
- Erectile dysfunction



# Genital Pathology

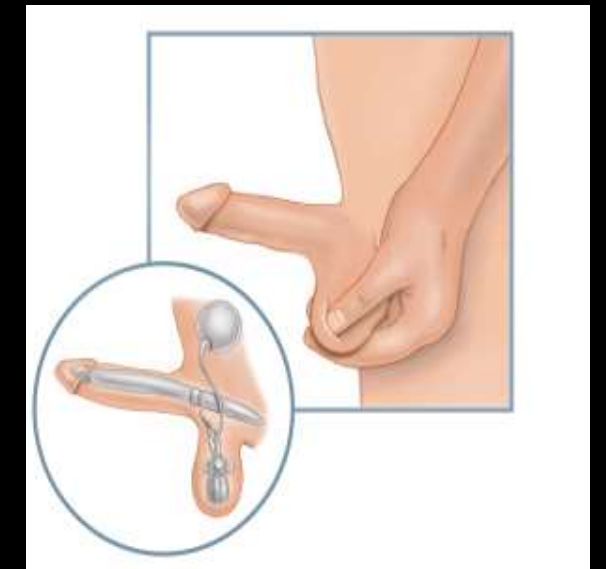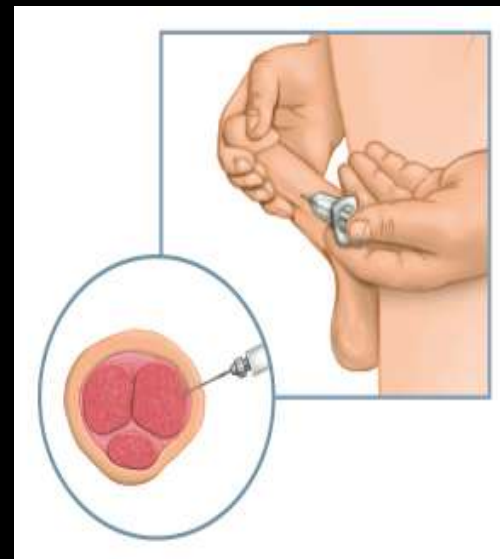
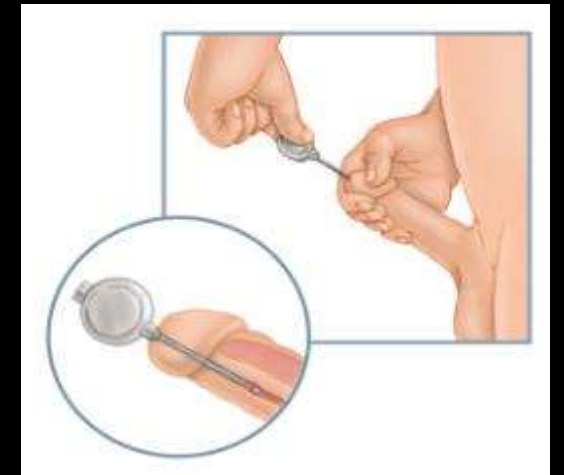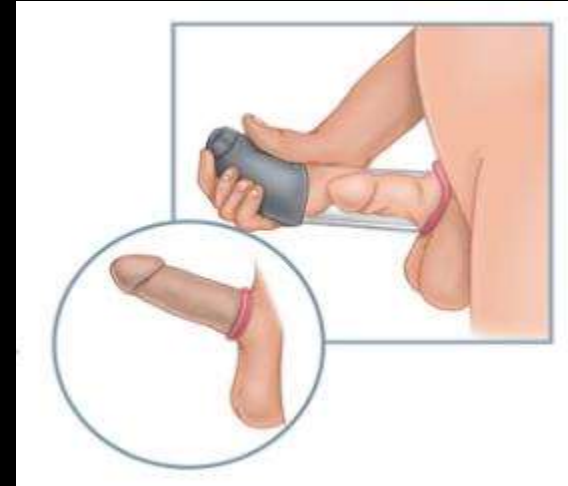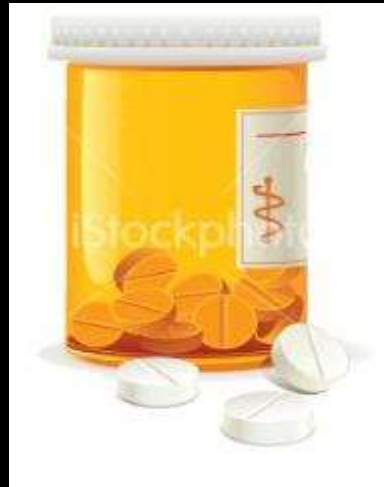- Herpes
- Hypospadias
- Stricture
- Peyronies' Disease
- Priapism



Peyronies Treatment Surgery by Professor Sava Perovic, MD, PhD University of Belgrade School of Medicine

# Erectile dysfunction

- 65% of men over age of 65 have ED
- DM, PVD, HTN, smoking, EtOH
- Medications
- Hypogonadism
- Psychological



# Management of Erectile Dysfunction

- Oral medications
  - tadalafil
  - sildenafil
  - vardenafil
  - Avanafil
- Injectable
  - Tri-mix
  - Caverject
- Urethral
- Testosterone
  - Topical
  - Injectable
  - Implant
  - Transdermal
  - Adverse side effects

# Bladder Disorders

- Cancer
- Chronic cystitis
- Overactive Bladder
- Incontinence
- Reflux
- Hematuria
- UTI

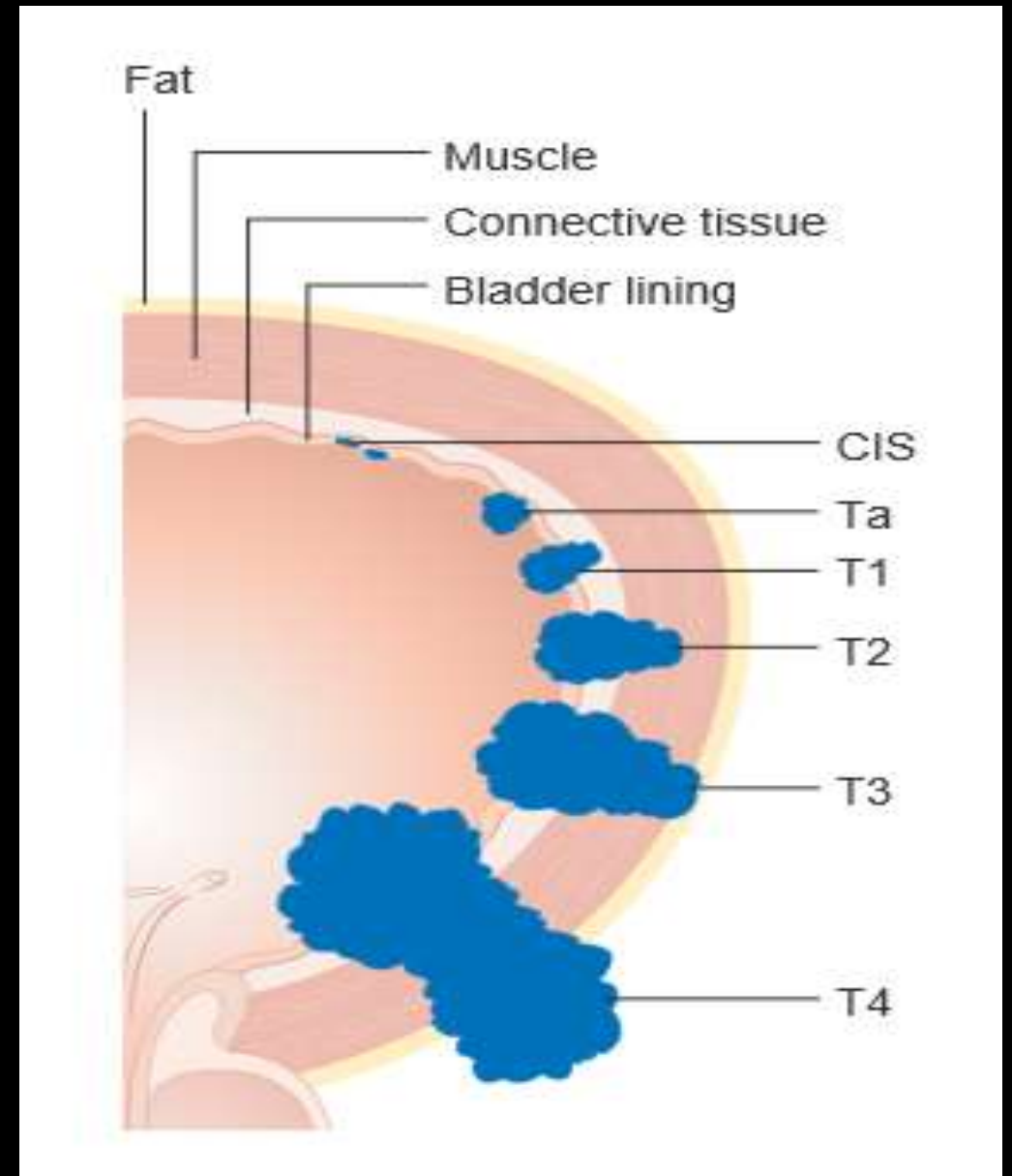


# Bladder cancer – risks, work up, rx

- **Tobacco**
  - **Paint**
  - **Dye**
  - **Chemicals**
- CT Urogram, Cytology, Cystoscopy  
(w/wo contrast of abd & pelvis)
  - Biopsy, surveillance q 3 months
  - BCG, 6 weeks once a week
  - Cystectomy – ostomy, pouch, diversion.

# Bladder Cancer

- Staging determines treatment
- Periodic biopsies or TURBT
- BCG treatment
- Cystectomy



# Chronic cystitis

- Vesicoureteral reflux
- Neurogenic bladder
- Obstruction
- Congenital Abnormalities
- Pelvic-ureteric obstruction
- Ureteric and urethral strictures
- Urolithiasis
- Bladder diverticuli
- Tumors
- Foreign Bodies
- Indwelling catheters
- Other
- Diabetes mellitus
- Renal failure
- Urinary diversions
- Urinary instrumentation

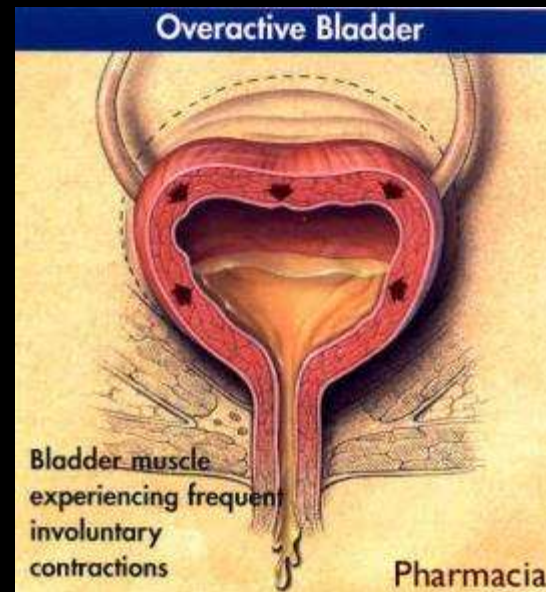
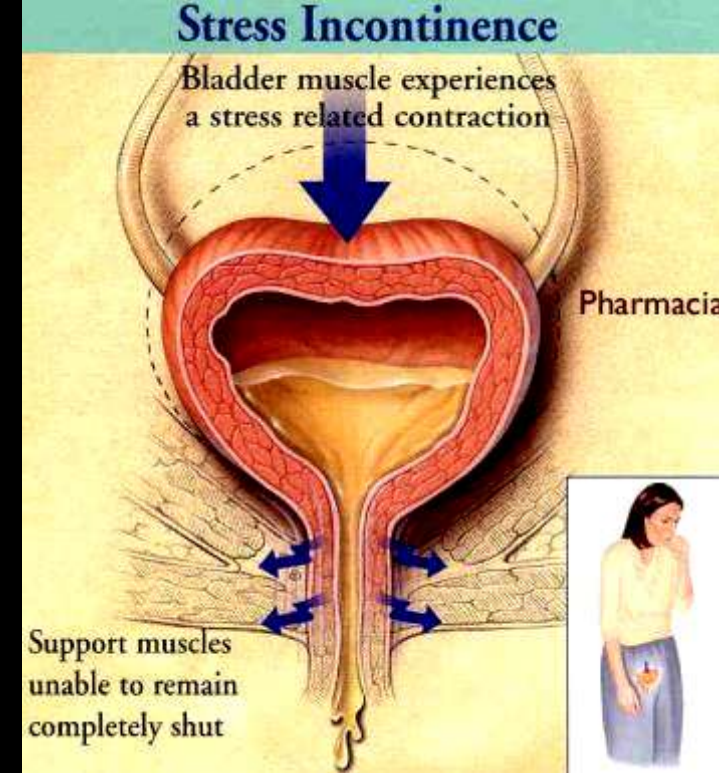


# Overactive Bladder

- Rule out retention, infection
- Trial of behavior modification
  - Diet
  - Weight Loss
  - Manage constipation
  - Irritants
- Anticholinergics
- mirbegron

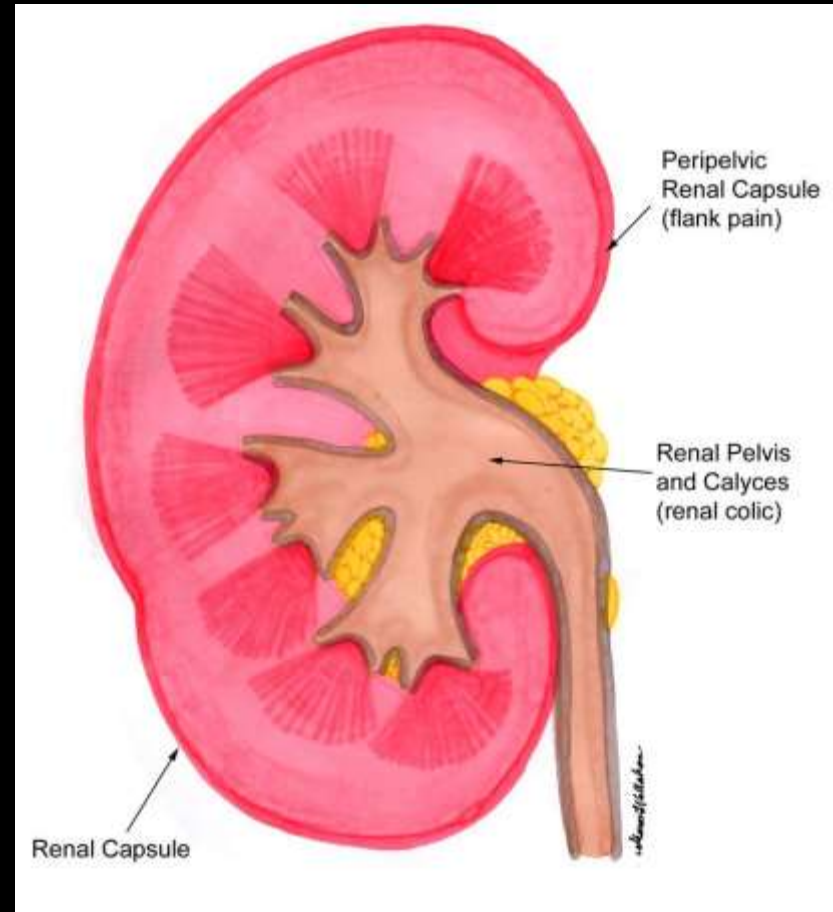
# Incontinence

- **Stress incontinence**
  - Lack of sphincter support
- **Overflow incontinence**
  - Obstruction
  - Atony of the bladder
- **Urge incontinence**
  - Gush of urine
  - Excess contractions
- **Mixed incontinence**

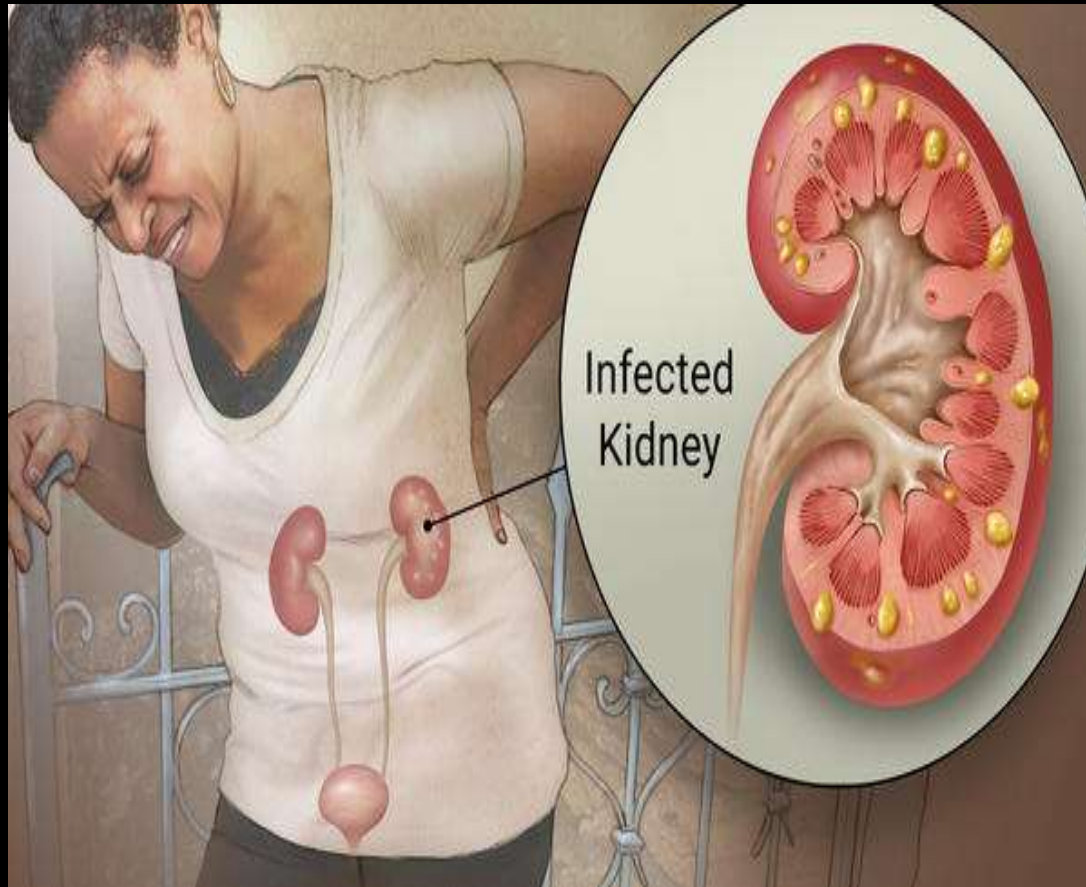


# Renal Pathology

- Pyelonephritis
- Nephro/ureterolithiasis
- Hydronephrosis
- Renal cell carcinoma
- Transitional cell carcinoma
- Wilm's Tumor



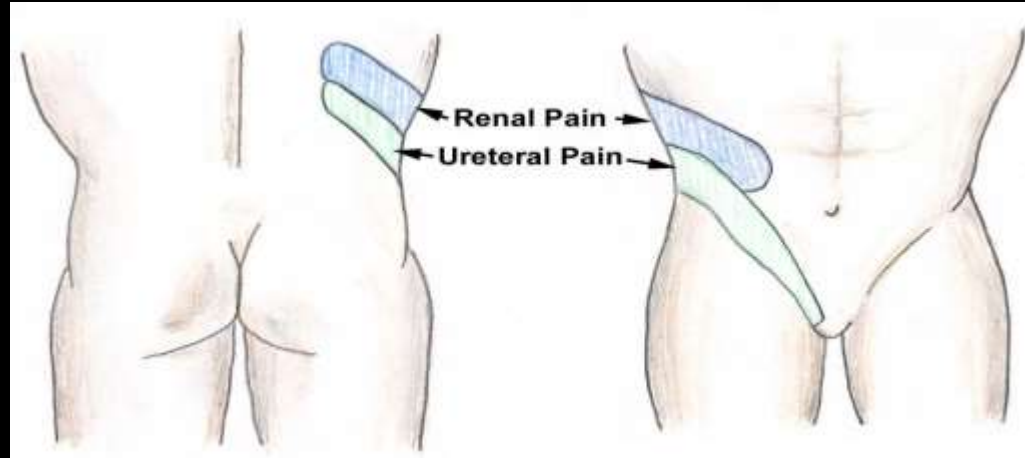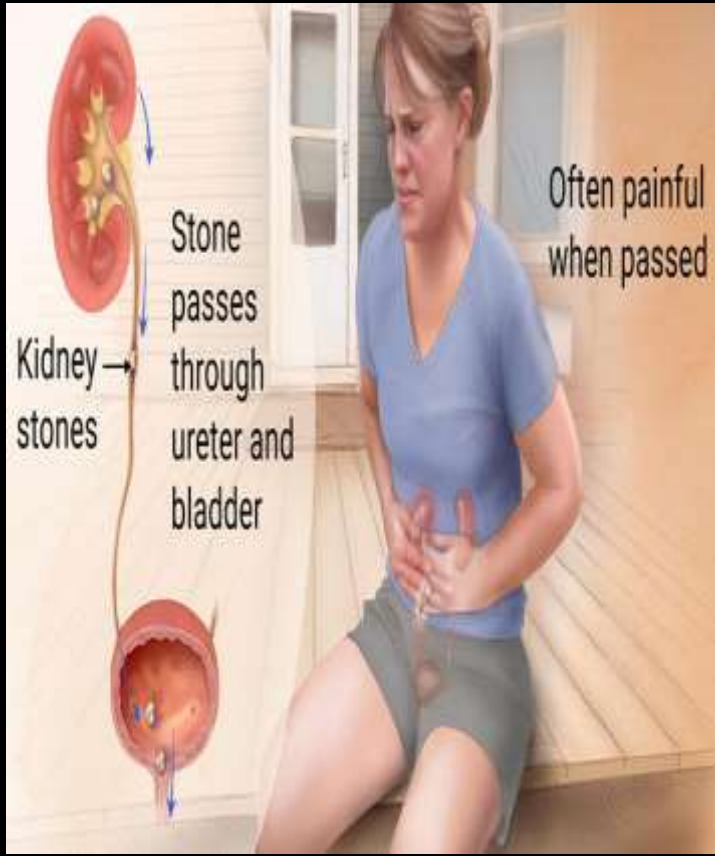# Renal Pathology-Pyelonephritis



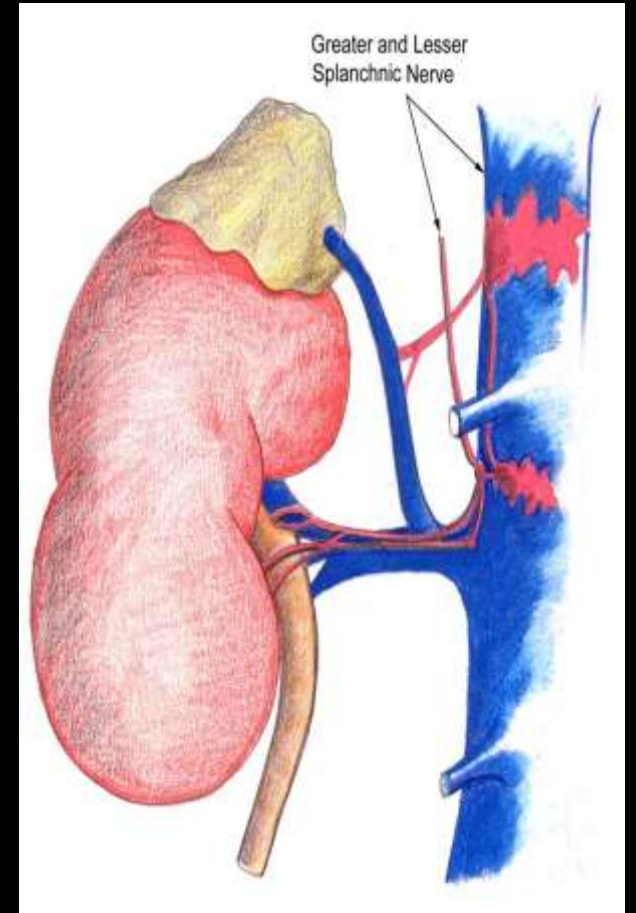
- Pain – dull, throbbing
- Chills & Fever
- Fatigue, malaise
- Urgency & frequency
- Nausea, abdominal pressure
- Jaundice, bile brown/dark yellow
- CVA tenderness
- Flank pain

# Renal Pathology-

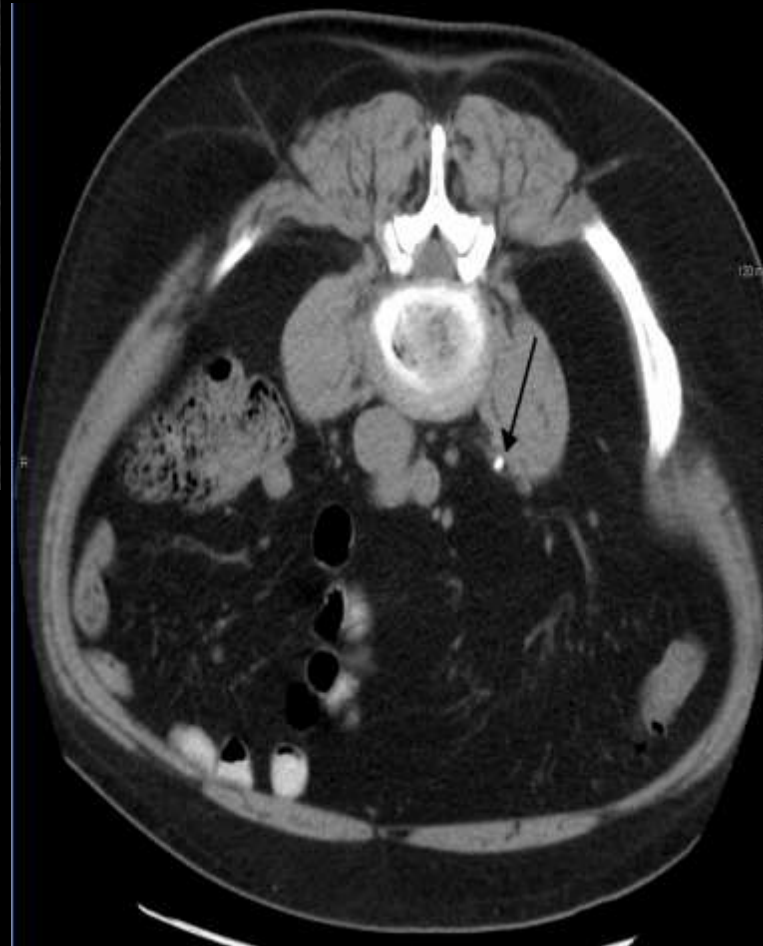
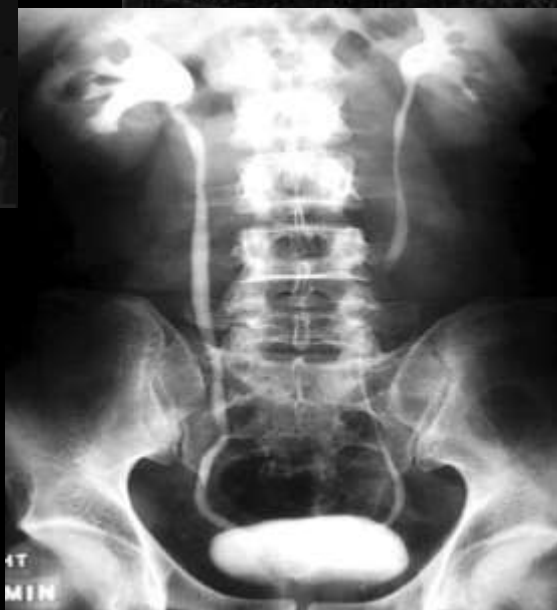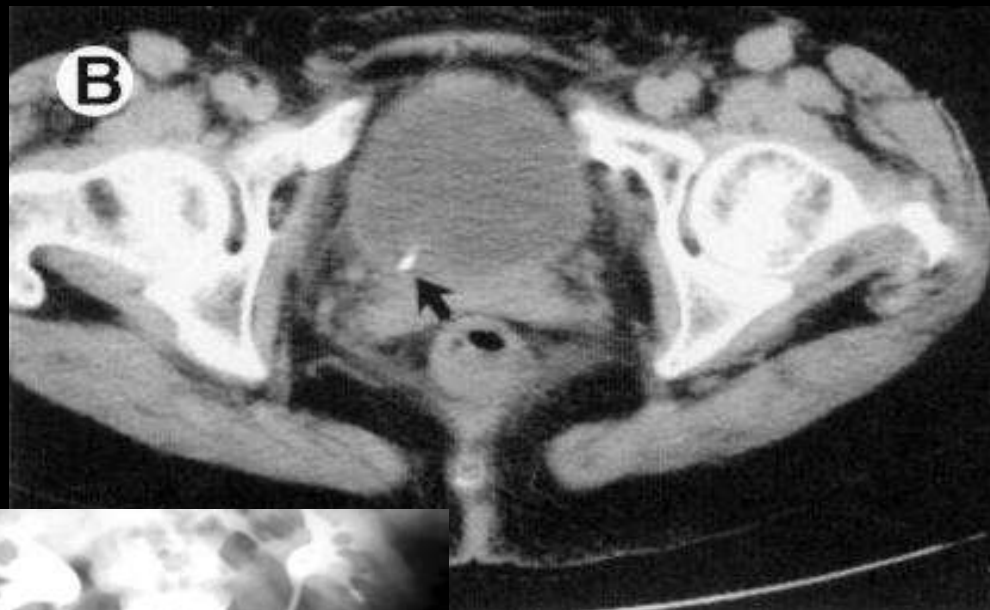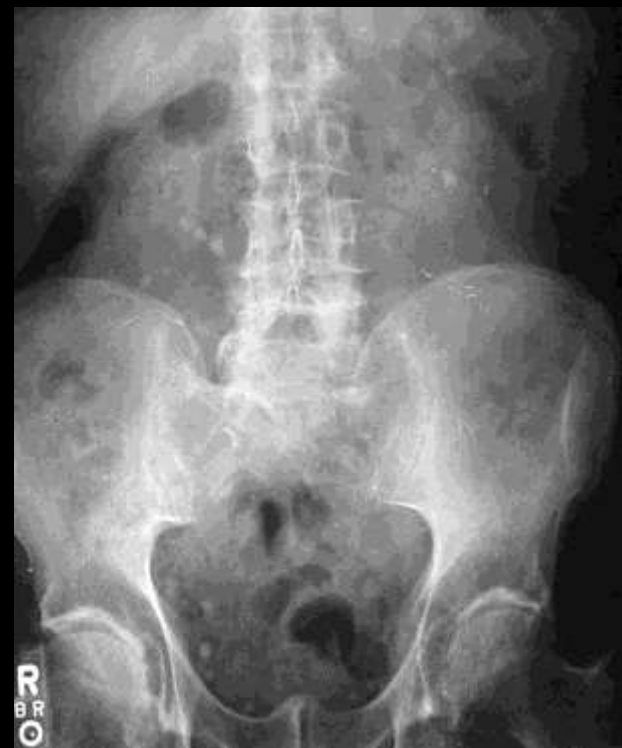## Nephro/ureteronephrolithiasis



- Calcium
- Uric acid
- Struvite
- Cysteine



# Renal Pathology - Ureteronephrolithiasis



# Renal Pathology - Ureteronephrolithiasis





- **Diagnosis**

- PE and UA
- KUB
- Non-contrast CT

- **Treatment**

- Size does matter
- Fluids
- Alpha blocker
  - Tamsulosin 0.4mg daily
  - Others
- Analgesia
- Memetic

- **Definitive treatment**

- Spontaneous passage  < 0.5-0.7
- Ureteroscopy/stent  obstruction
- ESWL  .5 – 1.5 cm, location
- Percutaneous (PCNL)  large > 1

- **Pathologic evaluation**

- **Prevention**

- Diet
- Caffeine
- Animal protein
- Gastric Bypass

# Renal Carcinoma

- **Wilm's Tumor**

- Symptoms

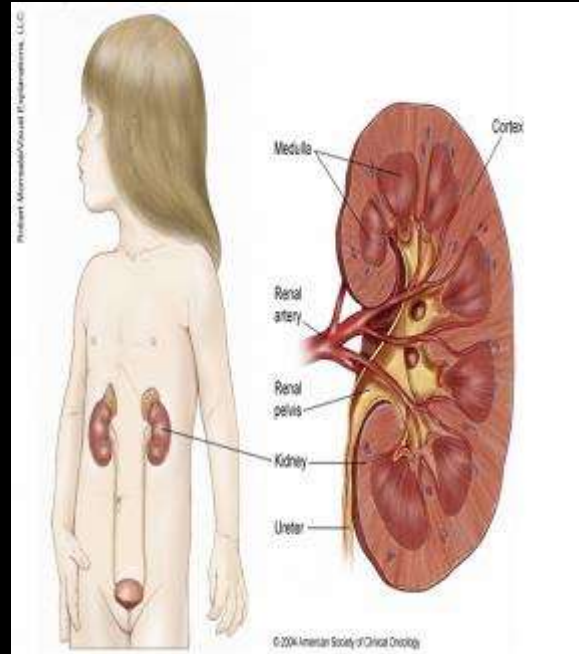
- Abdominal swelling
- Palpable abdominal mass
- Abdominal pain
- Fever
- Blood in the urine

- Etiology/epidemiology

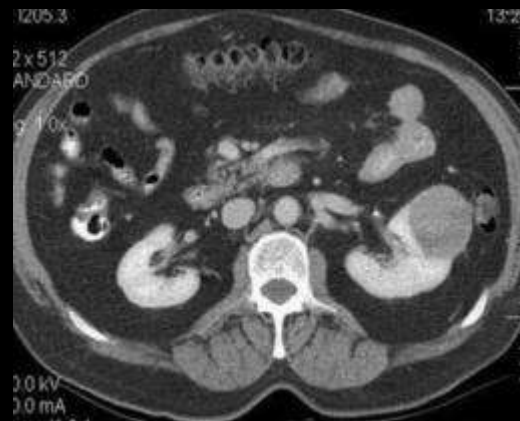
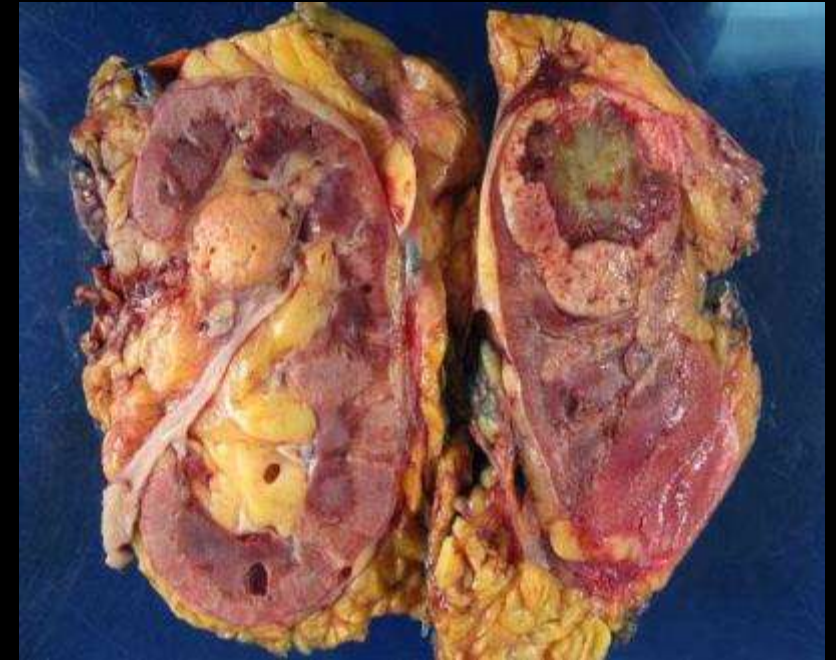
- Genetic
- Black increased/Asian lower

- Syndromes

- WAGR
- Denys-Drash
- Beckwith-Wiedemann



- **Renal Cell Carcinoma**





# Renal Cancer

- **Classic triad of symptoms in 10%**
  - Flank mass
  - Hematuria
  - Pain
- **Approximately 2/3 of patients have metastasis at presentation**
  - Only 1-3% will have a solitary metastasis
- **Renal cell carcinoma**
  - Clear cell RCC
  - Papillary RCC
  - Chromophobe RCC
- **Pseudotumors**
- **Oncocytomas**
  - Benign or malignant
- **Sarcoma**
  - Hypovascular
- **Benign cysts**
  - Most common benign renal mass

# Renal Pathology-**Renal Carcinoma**

- Clear cell papillary renal cell
- Clear cell papillary AND clear cell RCCa w/ smooth muscle stroma
- Tubulocystic RCCa
- Mucinous tubular & spindle cell
- Multilocular cystic clear cell RCCa
- Hereditary leiomyomatosis & RCCa
- Thyroid-like follicular RCCa
- Acquired cystic kidney disease associated
- RCCa with translocation
- Hybrid oncocytoma, chromophobe RCCa



# Hematuria

- Painless vs Painful
- Clots
  - Amorphous
  - Veriform
- Differential Diagnosis
- Diagnosis
  - CT urogram
  - Cystoscopy
  - cytology

# Hematuria

- P – period, pseudo heme
- P - prostate
- O - obstruction
- N – nephritis
- T - trauma
- T - tumor
- T – tuberculosis
- T – thrombosis
- H - hemotologic
- I – infection/inflammation
- S - stones

# Hematuria

PeePee on T4his



- Period, pseudo hematuria
- Prostate
- Obstruction
- Nephritis
- Trauma
- Tumor
- TB
- Thrombosis
- Hematologic
- Infection/Inflammation
- Stone

# Urinary Tract Infection

- **Urinalysis w/ C & S**
  - Bacteria, pyuria, RBC
- **Assess microscopic**
  - Counts, WBC
- **Symptomatic treatment**
  - Increase fluids
  - phenazopyridine
- **Treat to culture**
- **Short antibiotic therapy**
  - Nitrofurantoin 100mg PO BID 5-7
  - SMX/TMP DS PO BID 5-7 days
  - Monurol, fluoroquinolones,
- **Extended antibiotic**
  - Complicated UTI
    - Men, pregnant, DM
    - Immunocompromised
    - Stones, stents, catheters
    - Neurogenic bladder w/ catheters

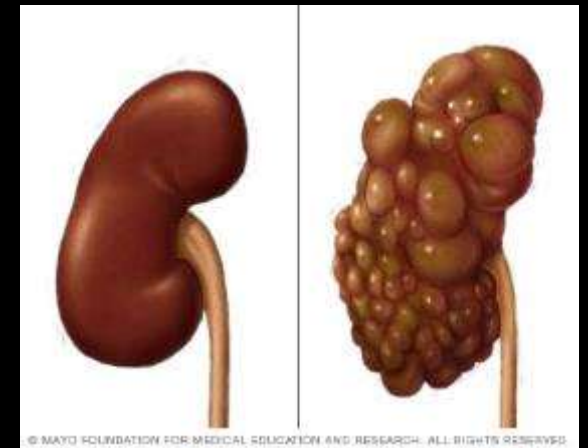
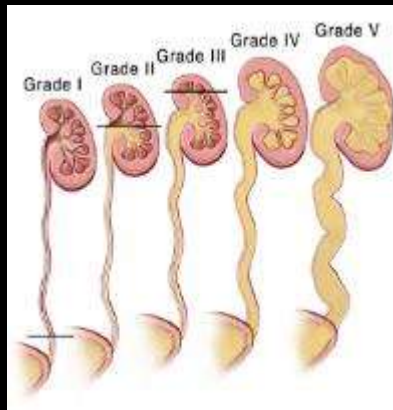
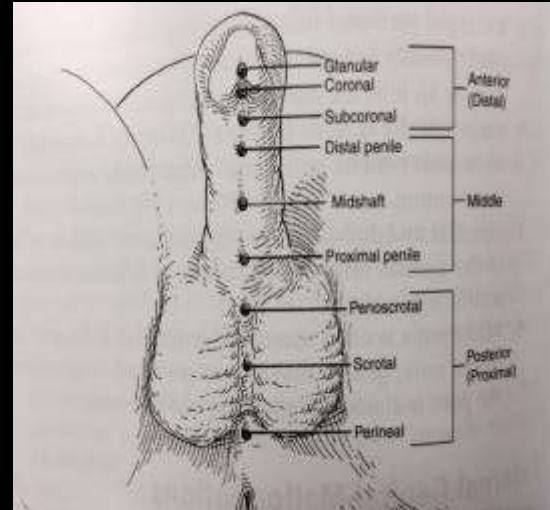
# Chronic Cystitis

- Radiation cystitis
- Interstitial cystitis
- Suprapubic catheters
- Neobladder
- Pelvic pain syndrom



# Congenital Disorders

- Vesicoureteral reflux
- Hypospadias
- Epispadias
- Cryptorchidism
- Polycystic kidney disease



***The END.....***

***whancock7@nc.rr.com***